

Medical University of South Carolina Charleston, SC

Modified Barium Swallow Study Fluoroscopic Evaluation of Swallowing Function CPT Code 92611

Evaluation Year: 2024

Reason for Study: Dysphagia
Referring Physician: Dr. Doe
Evaluating Clinician: Smith, Kate

Patient ID: D7CAA287-25BE

Study Number: 2

Patient Name:

MRN:

Status: Inpatient

Age: 68

Gender: Female

Height: 5 feet 6 inches

Current Weight: 125.0lbs

Body Mass Index: 20.17

MEDICAL HISTORY:

Primary (admitting) Diagnosis:

Aortic Aneurysm, with Rupture (I71.8)

Arrhythmia (I49.9)

Year of Onset or Diagnosis: 2024

Current Medications: Ibuprofen

Vitamins and Supplements: Vitamin C

Drug Allergies: Erythromycin, PNC

Food Allergies: Shellfish

Social History: Current Tobacco Use: cigarettes, less than 1 packs/day;

Current Alcohol Use: Wine, 1 Daily;

Current (pre-evaluation) Intake/Diet:

Route: PO

Diet Grade: Puree

Liquid Consistencies: Nectar

Pre-Study Functional Oral Intake Scale (FOIS): 5- Total oral intake of multiple consistencies requiring special preparation

Patient Self-Perception Rating Forms:

M.D. Anderson Dysphagia Inventory (MDADI): Global Score= (1), Total Score= (55), Mean= (2.89473684211) with a Multiple Mean of (57.8947368421) whereby 20 is low functioning and 100 is maximum functioning.

Dysphagia Handicap Index (DHI): Physical Domain Score= (20), Functional Domain Score= (20), Emotional Domain Score= (14) with a Total Score of (54) whereby 0 is no handicap and 120 represents a maximum handicap. Swallowing Severity Rating was (5)/7 whereby 1 is normal and 7 represents a severe problem.

Eating Assessment Tool (EAT-10): Overall Total was (18) whereby a score of 3 or higher is considered abnormal.

Pain: Chronic/Ongoing reported at time of study, Neck, rated 3 on scale 0-10

Barriers to Learning: Hearing Impaired

SUBJECTIVE:

Patient presents with chronic dysphagia following emergent trach secondary to MVC. Has participated in structured therapy for 8 weeks. Patient adherent to exercise program and recommendations.

OBJECTIVE:

Time-out: performed at 16:54

Evaluation Start: 16:55; Stop: 16:59

Tracheostomy tube present:

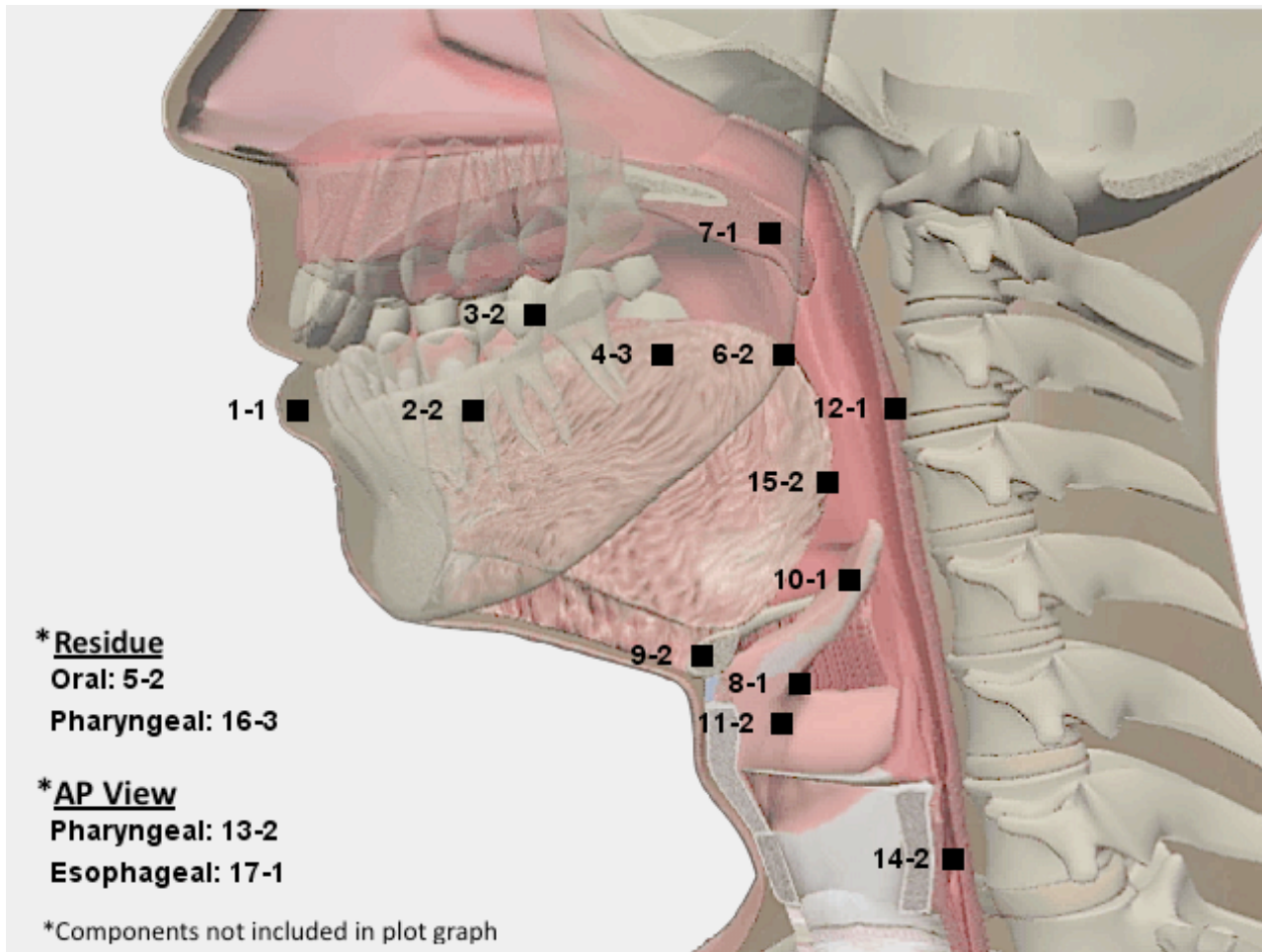
Shiley, 6, Single Cannula, PSMV

Patient Positioning: Seated 70-90 degrees

Viewing Planes: LAT & AP

Contrast: Commercially prepared, standardized Barium Viscosities were used and graduated from thin liquid to pudding consistency; administered via teaspoon, 5 ml boluses and by cup or straw in single & sequentially swallowed boluses, as tolerated; Solid evaluated with ½ shortbread cookie/3ml ba pudding coating, as tolerated.

MBSImP ID: D7CAA287-25BE



MBSImP Overall Impression: Lip closure for intraoral bolus containment resulted in interlabial escape, without progression to the anterior lip. Tongue control during bolus hold resulted in posterior escape of less than half of the bolus. Bolus preparation and mastication demonstrated disorganized chewing/mashing with solid pieces of the bolus unchewed. Bolus transport/lingual motion was with repetitive/disorganized motion of the tongue. Oral residue was a collection on oral structures. Initiation of the pharyngeal swallow occurred as the bolus head was at the posterior laryngeal surface of the epiglottis. Soft palate elevation allowed a trace column of contrast or air between the soft palate and the pharyngeal wall. Laryngeal elevation was decreased, with partial superior movement of the thyroid cartilage/partial approximation of the arytenoids to the epiglottic petiole. Anterior hyoid excursion demonstrated no movement. Epiglottic movement resulted in partial inversion. Laryngeal vestibular closure was absent, resulting in a wide column of air/contrast within the laryngeal vestibule at the height of the swallow. Pharyngeal stripping wave was present, but diminished. Pharyngeal contraction resulted in unilateral bulging. Pharyngoesophageal segment opening demonstrated minimal distension/minimal duration, with marked obstruction of bolus flow. Tongue base retraction allowed a narrow column of contrast or air between the retracted tongue base and the posterior pharyngeal wall. Pharyngeal residue was the majority of contrast within or on pharyngeal structures. Esophageal clearance in the upright position resulted in esophageal retention.

COMPONENT Number and Descriptor		Scale	CURRENT Score and Descriptor	PREVIOUS Score and Descriptor at Time of Last Study
1	Lip Closure	(0-4)	1 Resulted in interlabial escape, without progression to the anterior lip.	0 Resulted in no labial escape.
2	Tongue Control/Bolus Hold	(0-3)	2 Resulted in posterior escape of less than half of the bolus.	1 Allowed bolus escape to the lateral buccal cavity/floor of mouth.
3	Bolus Prep/Mastication	(0-3)	2 Demonstrated disorganized chewing/mashing with solid pieces of the bolus unchewed.	2 Demonstrated disorganized chewing/mashing with solid pieces of the bolus unchewed.
4	Bolus Transport/Lingual Motion	(0-4)	3 Was with repetitive/disorganized motion of the tongue.	3 Was with repetitive/disorganized motion of the tongue.
5	Oral Residue	(0-4)	2 Was a collection on oral structures.	4 Resulted from minimal to no clearance of the bolus.
6	Initiation of Pharyngeal Swallow	(0-4)	2 Occurred as the bolus head was at the posterior laryngeal surface of the epiglottis.	4 Was not visible at any level.
7	Soft Palate Elevation	(0-4)	1 Allowed a trace column of contrast or air between the soft palate and the pharyngeal wall.	3 Allowed bolus escape to the nasal cavity.
8	Laryngeal Elevation	(0-3)	1 Was decreased, with partial superior movement of the thyroid cartilage/partial approximation of the arytenoids to the epiglottic petiole.	2 Was incomplete, as indicated through minimal superior movement of thyroid cartilage with minimal approximation of the arytenoids to the epiglottic petiole.
9	Anterior Hyoid Excursion	(0-2)	2 Demonstrated no movement.	2 Demonstrated no movement.
10	Epiglottic Movement	(0-2)	1 Resulted in partial inversion.	2 Resulted in no inversion.
11	Laryngeal Vestibular Closure	(0-2)	2 Was absent, resulting in a wide column of air/contrast within the laryngeal vestibule at the height of the swallow.	2 Was absent, resulting in a wide column of air/contrast within the laryngeal vestibule at the height of the swallow.
12	Pharyngeal Stripping Wave	(0-2)	1 Was present, but diminished.	2 Was absent.
13	Pharyngeal Contraction	(0-3)	2 Resulted in unilateral bulging.	0 Was complete.
14	Pharyngoesophageal Segment Opening	(0-3)	2 Demonstrated minimal distension/minimal duration, with marked obstruction of bolus flow.	3 Yielded no distension, resulting in total obstruction of flow.
15	Tongue Base Retraction	(0-4)	2 Allowed a narrow column of contrast or air between the retracted tongue base and the posterior pharyngeal wall.	3 Allowed a wide column of contrast or air between the retracted tongue base and the posterior pharyngeal wall.
16	Pharyngeal Residue	(0-4)	3 Was the majority of contrast within or on pharyngeal structures.	3 Was the majority of contrast within or on pharyngeal structures.
17	Esophageal Clearance (upright)	(0-4)	1 Resulted in esophageal retention.	3 Resulted in esophageal retention with incidence of retrograde bolus flow through the pharyngoesophageal segment.

Oral Impairment Score: 11
Pharyngeal Impairment Score: 17
Esophageal Impairment Score: 1

Laryngeal Penetration and Aspiration:

Neither penetration nor aspiration was observed in today's study with Cookie, Pudding-thick. Both Penetration and Aspiration were observed in today's study. Honey-thick Contrast entered the airway, remained above the vocal folds, and was ejected from the airway. Nectar-thick, Thin Contrast entered the airway, passed below the vocal folds, and were not ejected from the trachea despite effort.

Structural Abnormalities Noted:

Impeded:	Redirected:	Contributed to:	Hindered:	Improved:	Decreased:	Prevented:
Cervical Hardware noted, but had no functional significance.						

ASSESSMENT:

The patient's performance in today's study indicated impairment in swallowing as outlined in the table below:

Physiologic Component	Functional Significance			
	Impeded:	Redirected:	Contributed to:	Hindered:
Laryngeal elevation			aspiration	
Epiglottic movement			aspiration	
Laryngeal vestibular closure			aspiration	
Pharyngeal contraction			pharyngeal residue	
Tongue base retraction			pharyngeal residue	

Clinician Assessment:

Patient presents with improved swallow function as indicated in table above. Salient features include tongue base retraction and laryngeal vestibular closure.

The following compensatory strategies have not been used until today's study, but when employed, improved swallowing function:

Head Turn Right decreased Pharyngeal Residue

The following compensatory strategies have been used in therapy as well as in today's study and improved swallowing function:

Nectar-thick Liquid eliminated Aspiration
Nectar-thick Liquid decreased Penetration

The following exercises have been used in therapy and improvement(s) in swallowing function was/were seen today:

Effortful Swallow – SEMG increased Pharyngeal Residue
Mendelsohn Maneuver – SEMG decreased Aspiration
Masako Maneuver decreased Pharyngeal Residue

PLAN:**Intake Recommendations:**

Route: PO
Diet Grade: Mechanical Soft
Liquid Consistencies: Nectar,
Post-Study Functional Oral Intake Scale (FOIS): 6- Total oral intake with no special preparation, but must avoid specific foods or liquid items

Therapy Recommendations:

Therapy will be continued
Frequency per Week: 1
Number of Weeks: 4

The following compensatory strategies and/or therapeutic exercises will be part of the upcoming therapy/management plan:

Effortful Swallow – SEMG
Mendelsohn Maneuver – SEMG
Shaker Head Lifts
Masako Maneuver

Prognosis for Improvement: The prognosis for the patient to meet nutritional needs by mouth is good based on degree of impairment, stimulability for treatment, level of motivation, support system, improvement on today's study.

Patient's Personal Goals:

To eat a hamburger.

Long Term Goals:

- The patient will tolerate the least restrictive diet with a safe/efficient swallow to maintain adequate nutrition and hydration.
- The patient will demonstrate improved swallowing function via repeat clinical evaluation, videoendoscopy/videofluoroscopy and/or patient self-rating scores.
- The patient and/or family will participate in further education for swallowing goals.

Short Term Goals:

- Diet
 - The patient will tolerate a mechanical soft diet with nectar thick liquids without signs or symptoms of penetration/aspiration 90% of the time.
 - The patient will participate in therapeutic PO trials with the SLP.
- Guidelines
 - The patient will comply with/recall the following guidelines/strategies 100% of the time with minimal cuing: Nectar-thick Liquid, Head Turn Right, Liquid Wash, Additional Swallow(s) per Bolus, Effortful Swallow (used during PO intake), Mendelsohn Maneuver (used during PO intake).
- Independent Home Exercise
 - The patient will perform 10 repetitions of the Effortful Swallow, Mendelsohn Maneuver, Shaker Head Lifts, Masako Maneuver 3 times a day with 90% accuracy and minimal cuing as part of a home exercise program.
- Structured Therapy
 - The patient will demonstrate 80% accuracy and require moderate cuing in structured swallowing therapy with the SLP using the following exercises/therapy approaches and therapy assisted devices: Effortful Swallow, Mendelsohn Maneuver, Shaker Head Lifts, Masako Maneuver, EMST (Expiratory Muscle Strength Training), EMST 150 (Expiratory Muscle Strength Trainer), sEMG (Surface Electromyography), .
- Education
 - The patient, family, treating slp will verbalize/demonstrate understanding of the results of this evaluation, the above recommendations, and the swallowing guidelines.

Education:

Education regarding findings from today's study and plans for therapy were provided to Patient and family/caregiver through Verbal Instruction, Written Instruction, Demonstration. Understanding was expressed by the Patient and family/caregiver.

Kate Smith, MS, CCC-SLP